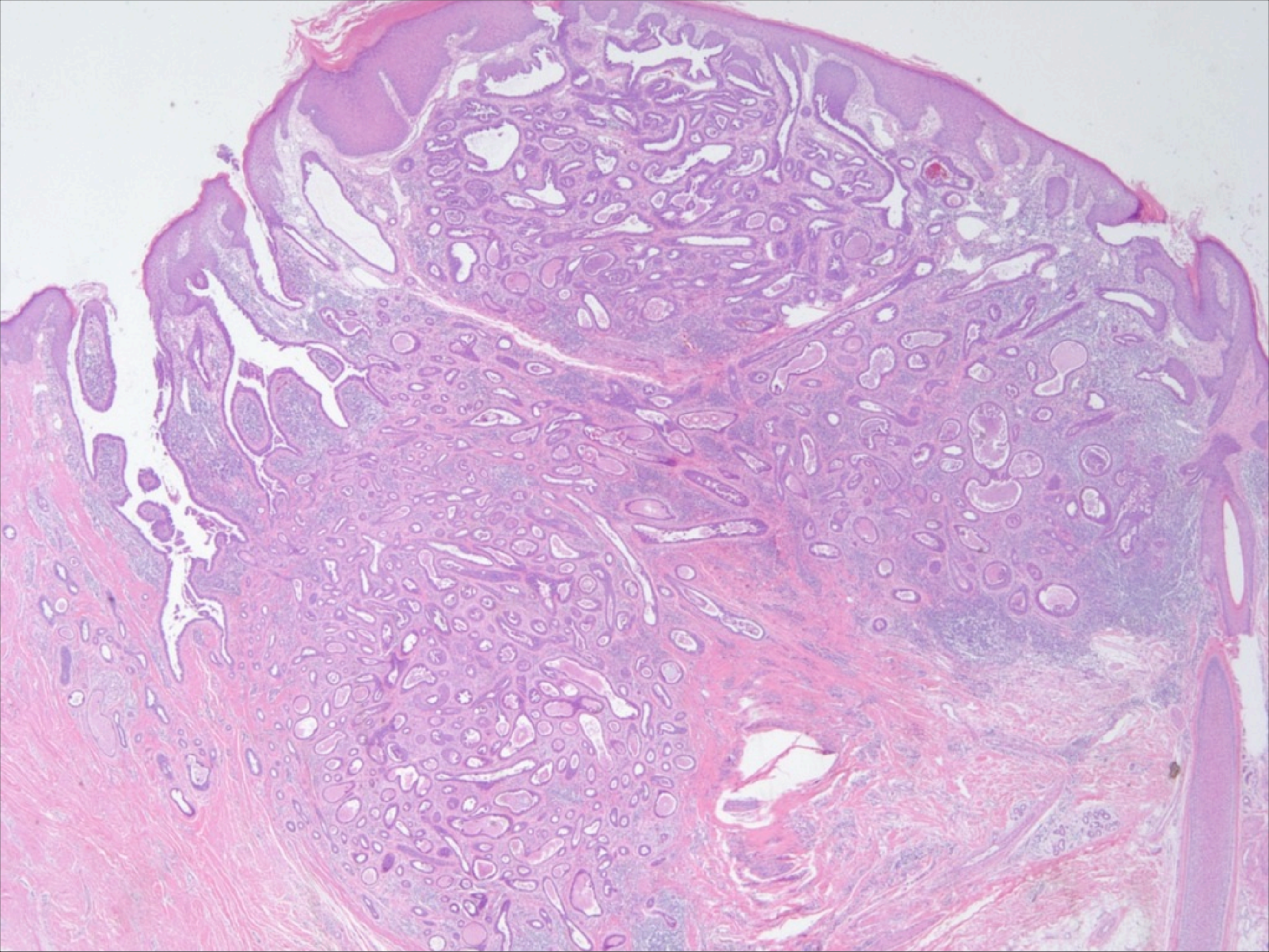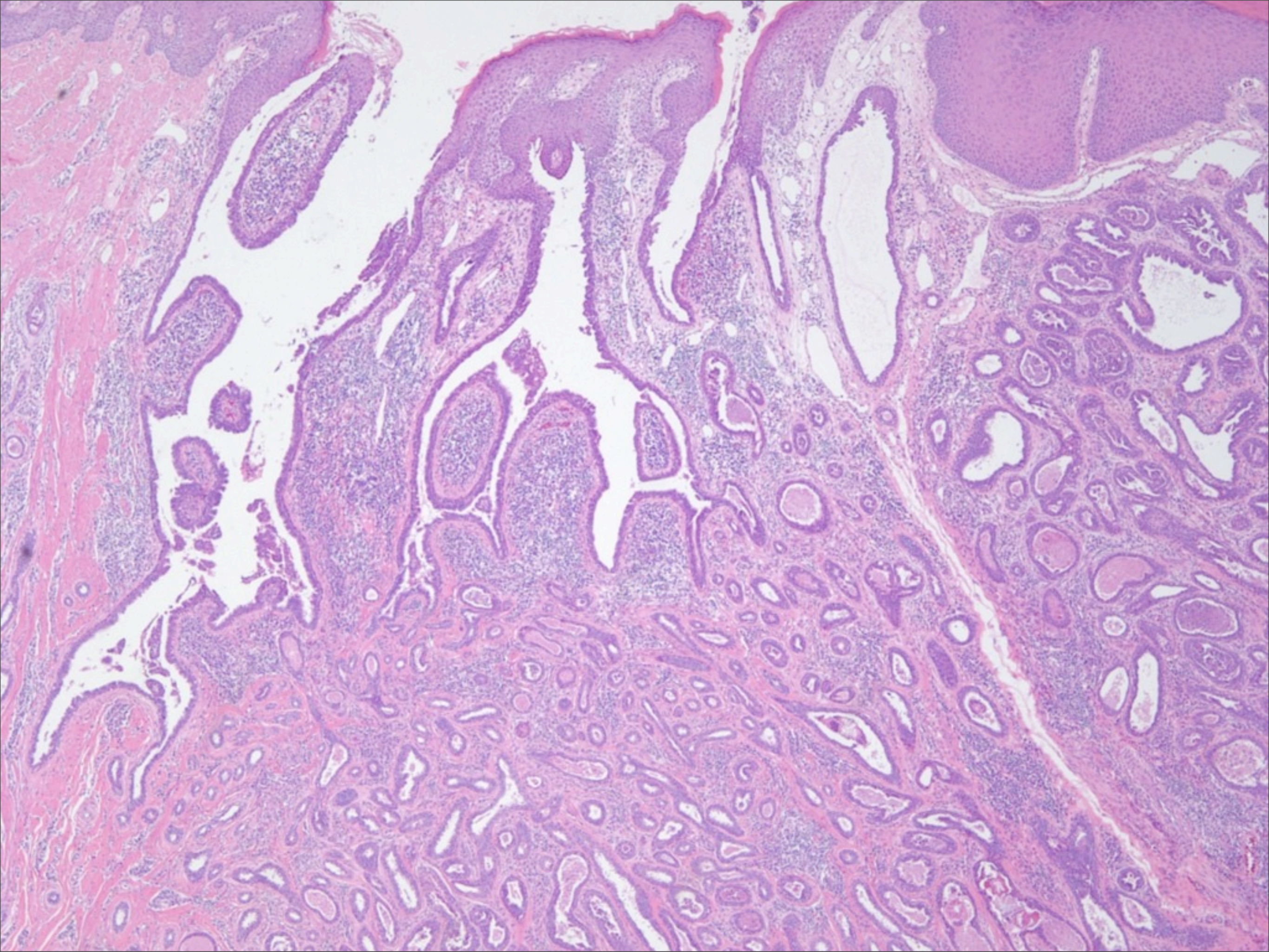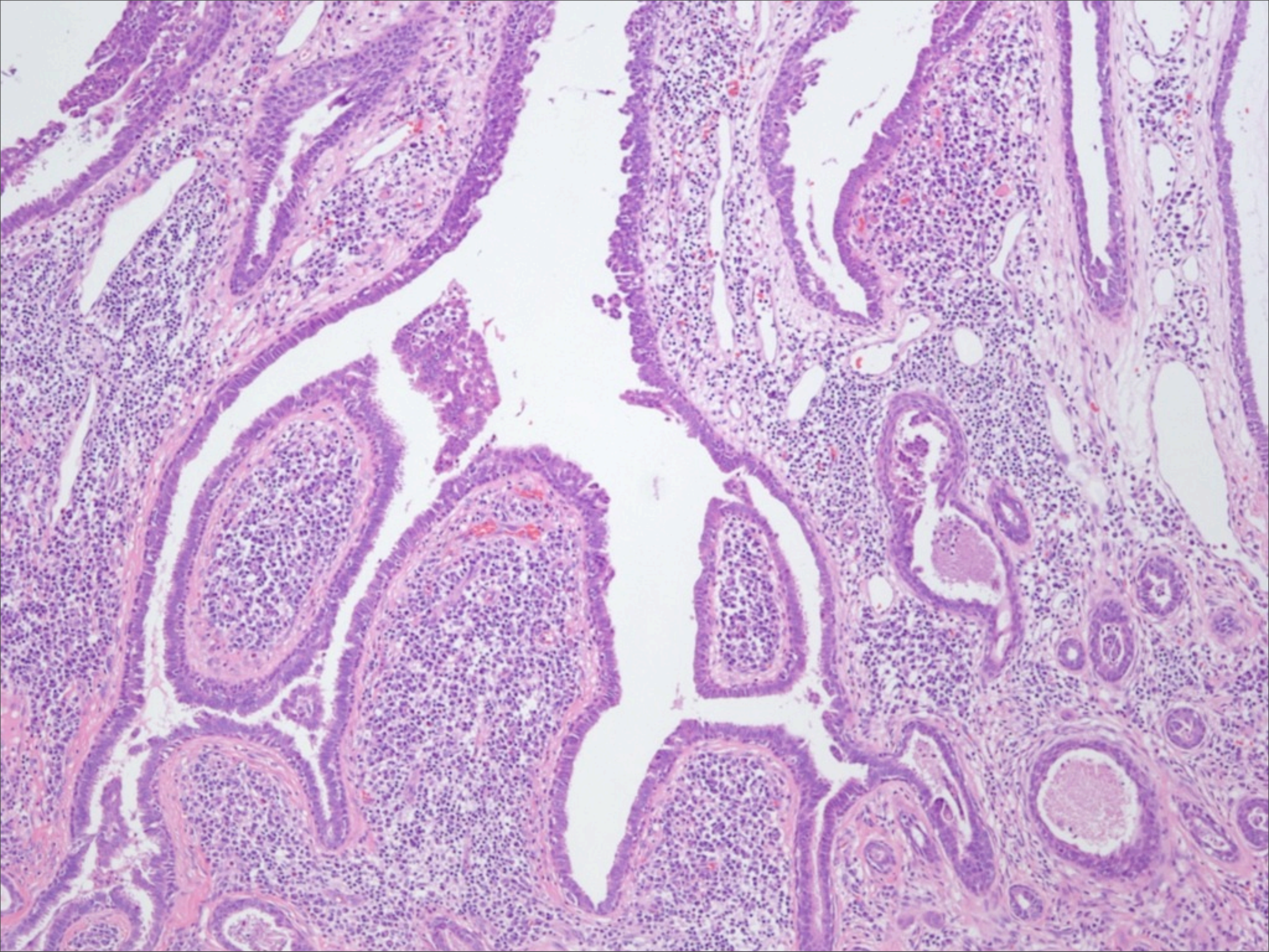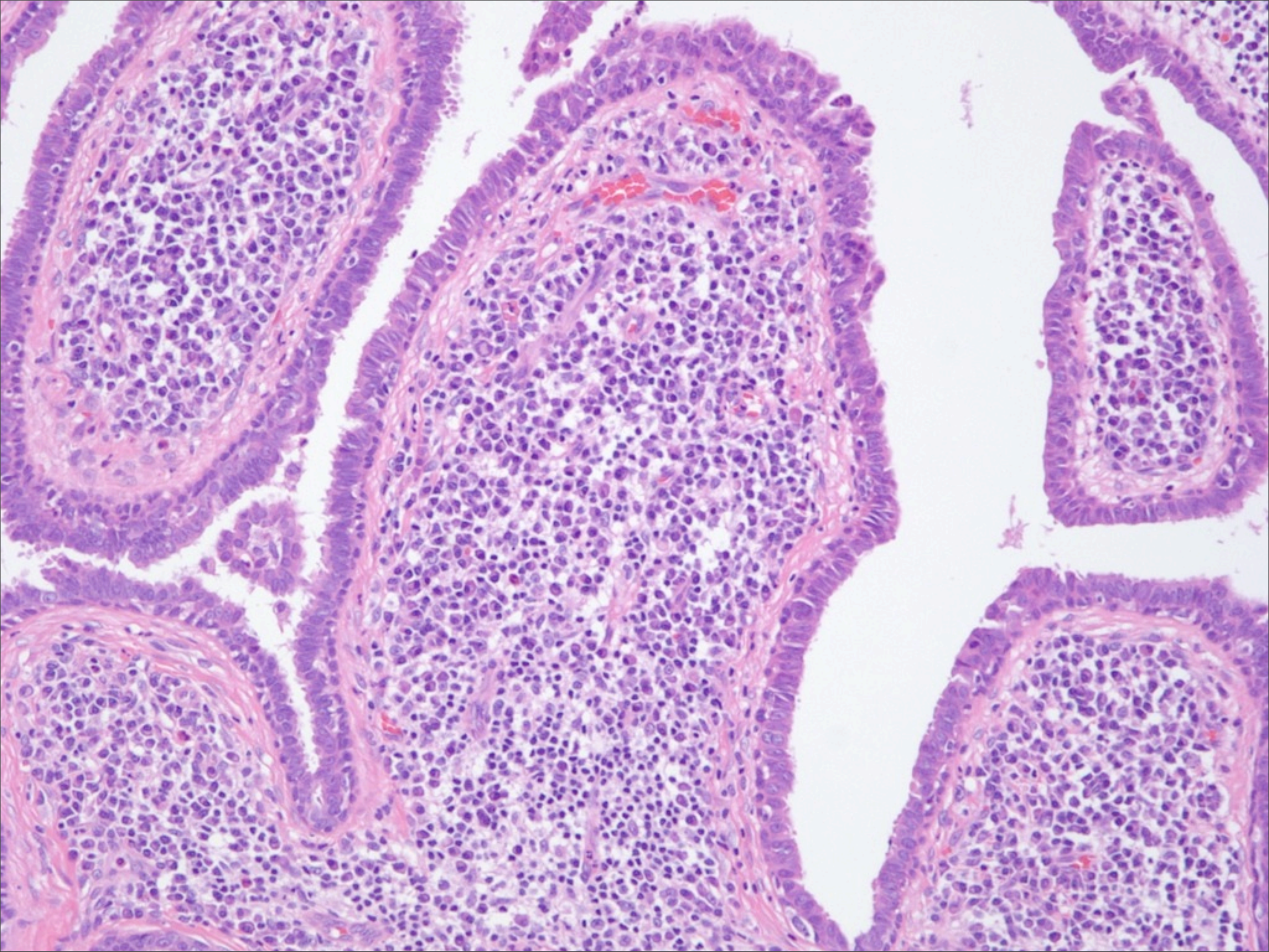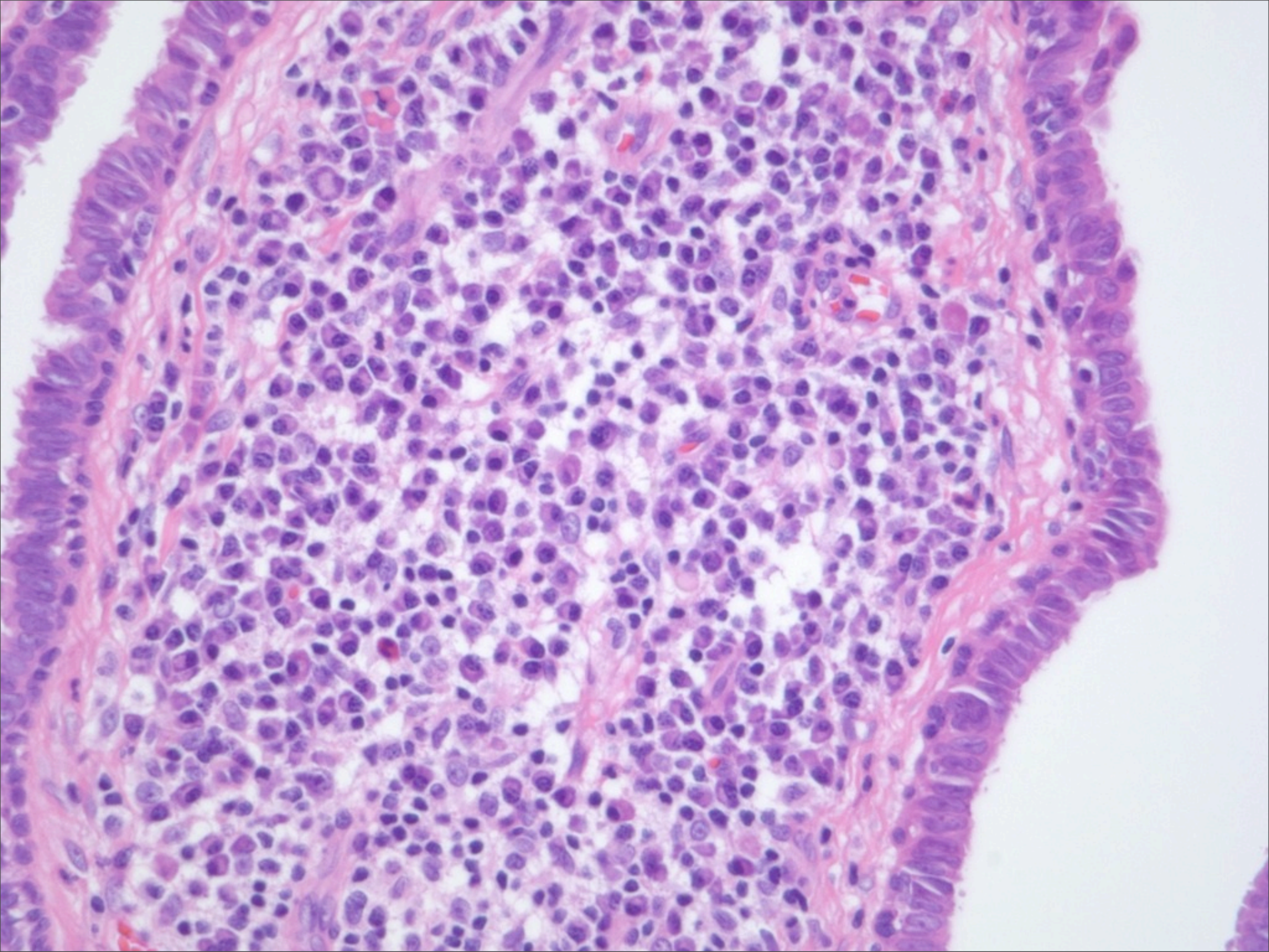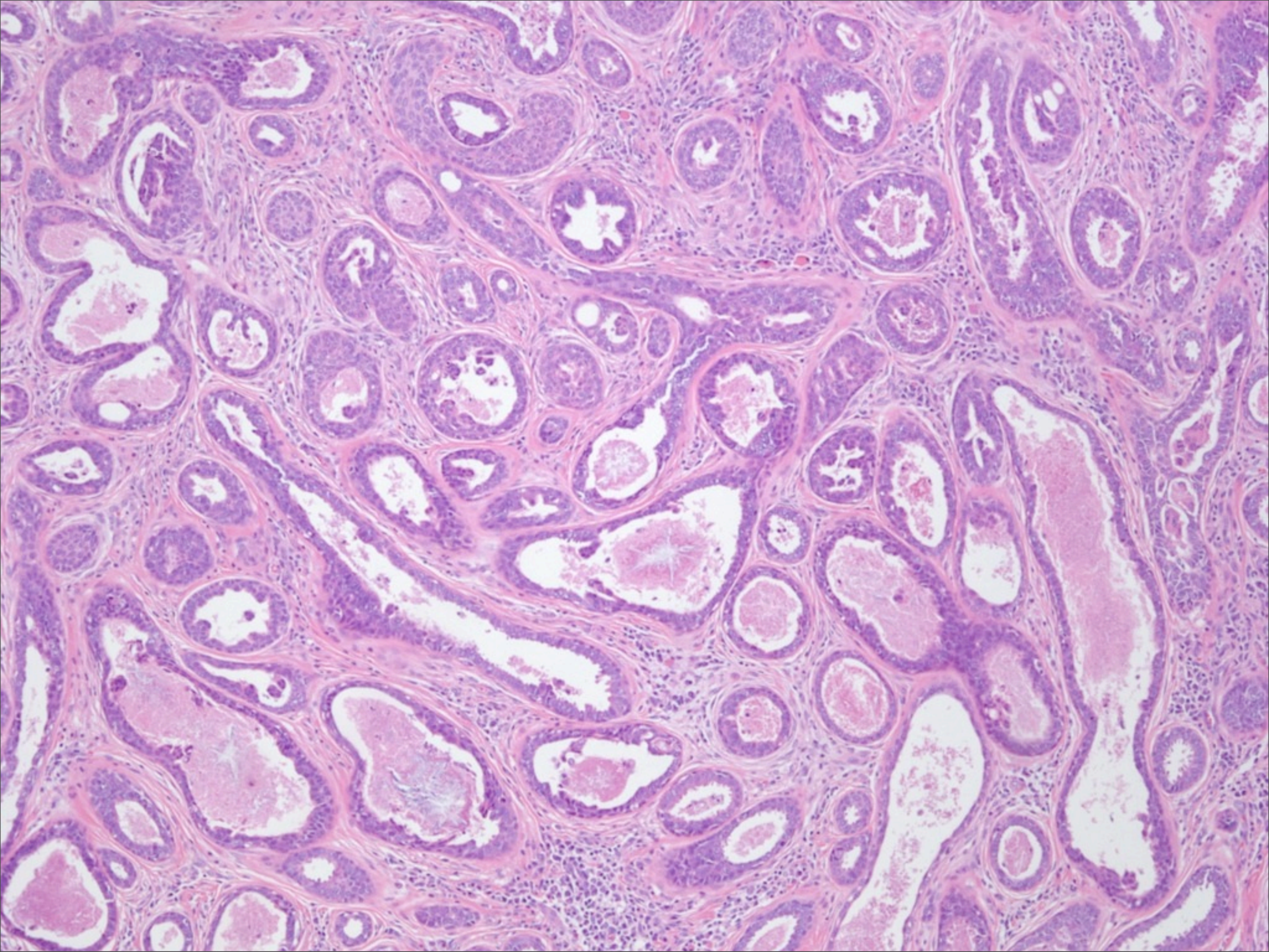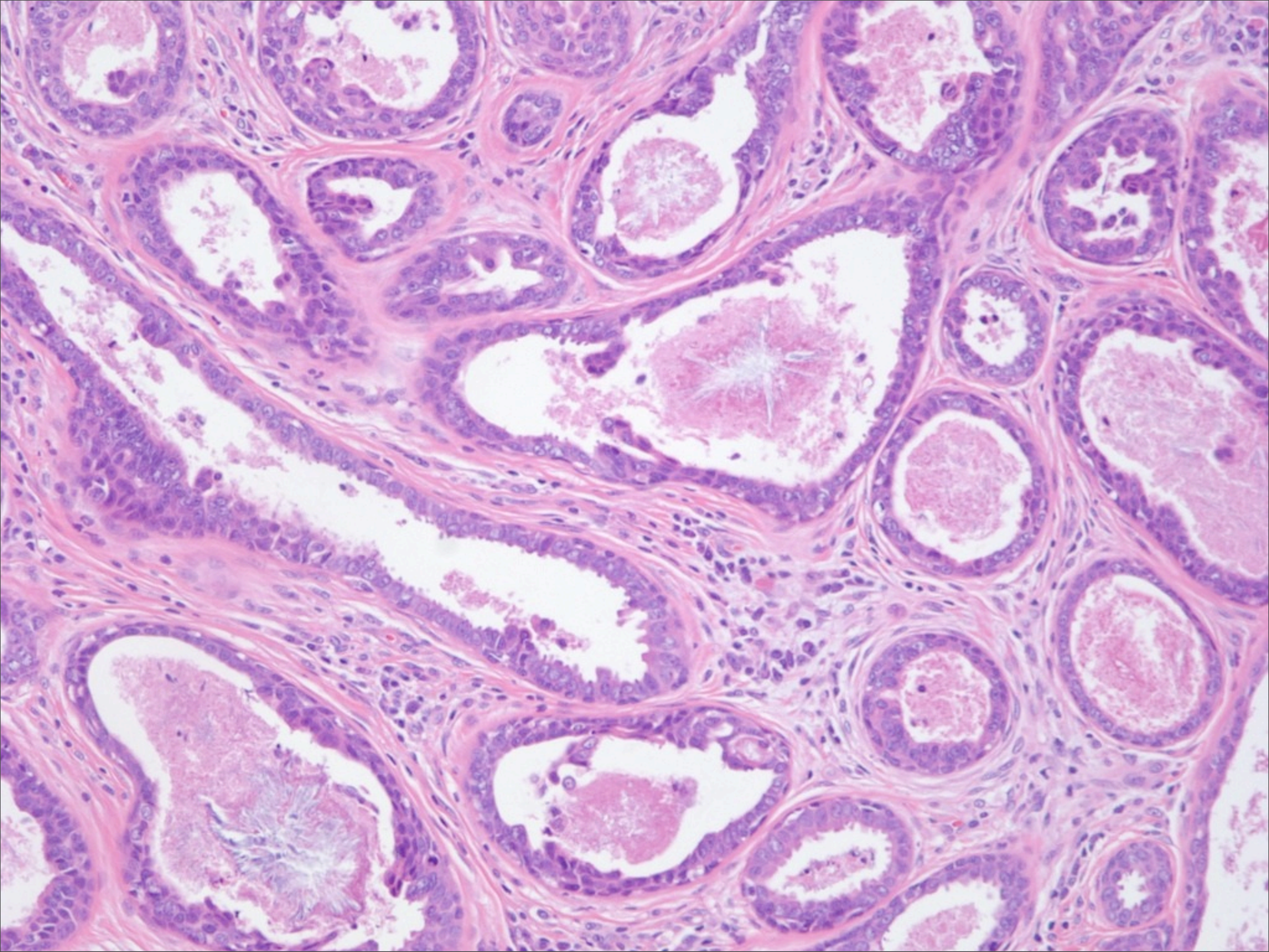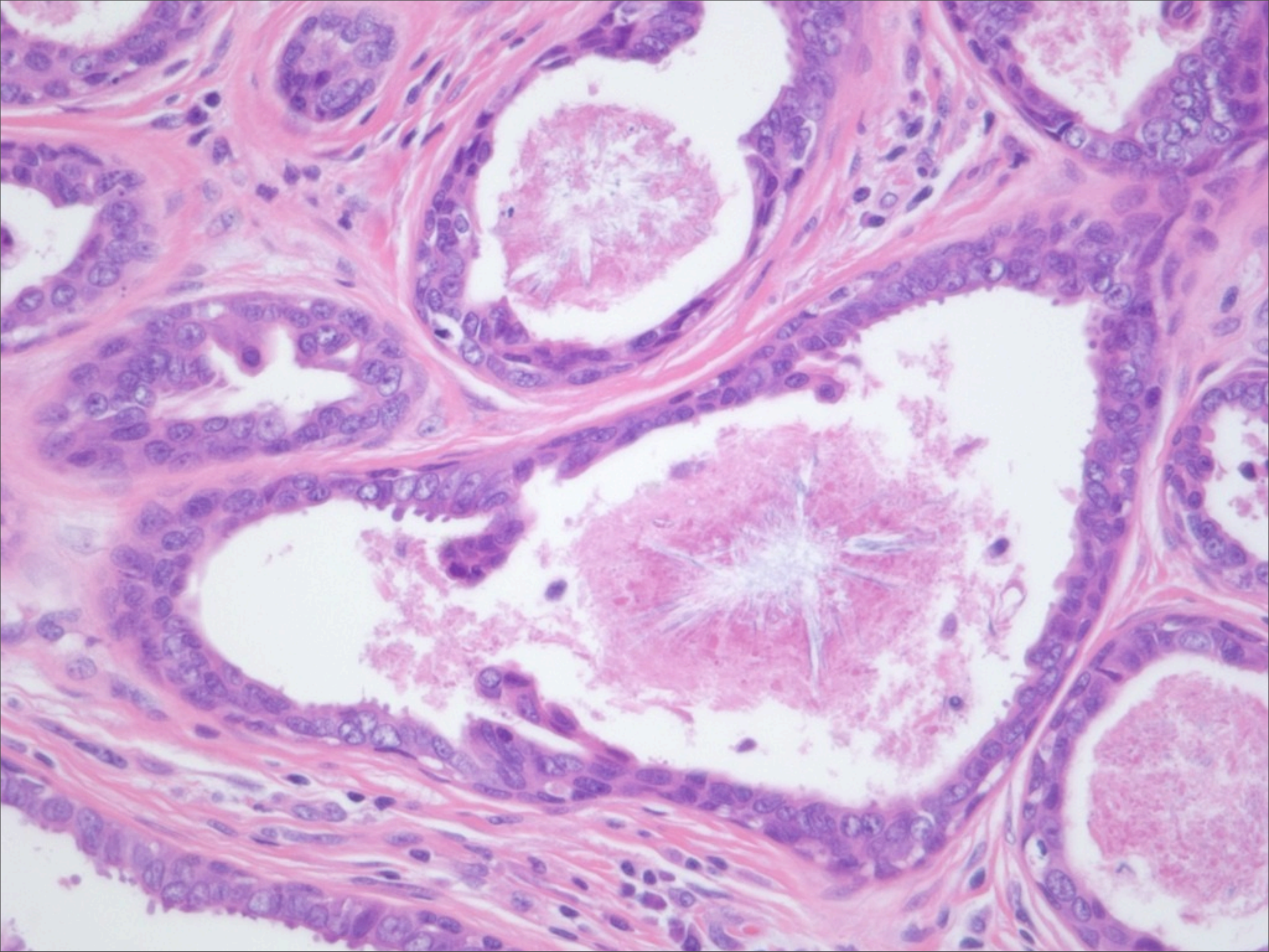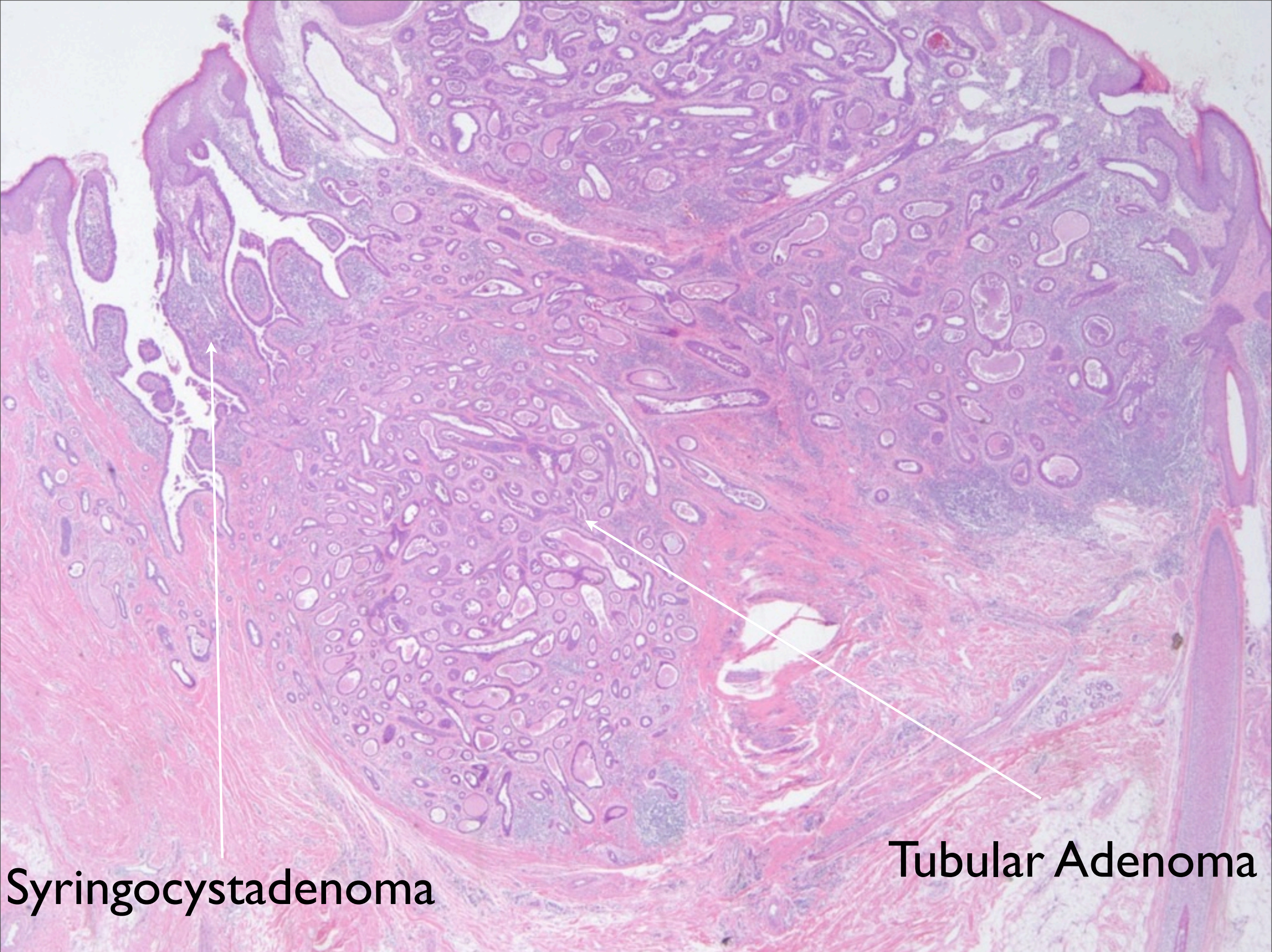


Syringocystadenoma Papilliferum arising with a Tubular Apocrine Adenoma



Syringocystadenoma

Tubular Adenoma